






RESEARCH ARTICLE

Magnetic resonance imaging findings in Kenyans and South Africans with active convulsive epilepsy: An observational study

Symon M. Kariuki^{1,2}  | Ryan G. Wagner³  | Roxana Gunny⁴ | Felice D'Arco⁴  | Martha Kombe¹ | Anthony K. Ngugi⁵ | Steven White⁶ | Rachael Odhiambo⁵ | J. Helen Cross⁷  | Josemir W. Sander^{8,9,10,11,12}  | Charles R. J. C. Newton^{1,2}

¹Neurosciences Unit, KEMRI-Wellcome Trust Research Programme, Kilifi, Kenya

²Department of Psychiatry, University of Oxford, Oxford, UK

³MRC/Wits Rural Public Health and Health Transitions Research Unit (Agincourt), School of Public Health, Faculty of Health Sciences, University of the Witwatersrand, Johannesburg, South Africa

⁴Department of Neuroradiology, Great Ormond Street Hospital, London, UK

⁵Department of Population Health, Medical College, Aga Khan University of East Africa, Nairobi, Kenya

⁶Cromwell Hospital, London, UK

⁷Developmental Neurosciences, UCL, NIHR BRC Great Ormond Street Institute of Child Health, London, UK

⁸Department of Clinical & Experimental Epilepsy, UCL Queen Square Institute of Neurology, London, UK

⁹Chalfont Centre for Epilepsy, Chalfont St Peter, UK

¹⁰Stichting Epilepsie Instellingen Nederland (SEIN), Heemstede, The Netherlands

¹¹Department of Neurology, West China Hospital, Chengdu, China

¹²Institute of Brain Science & Brain-Inspired Technology, Sichuan University, Chengdu, China

Abstract

Objective: Focal epilepsy is common in low- and middle-income countries. The frequency and nature of possible underlying structural brain abnormalities have, however, not been fully assessed.

Methods: We evaluated the possible structural causes of epilepsy in 331 people with epilepsy (240 from Kenya and 91 from South Africa) identified from community surveys of active convulsive epilepsy. Magnetic resonance imaging (MRI) scans were acquired on 1.5-Tesla scanners to determine the frequency and nature of any underlying lesions. We estimated the prevalence of these abnormalities using Bayesian priors (from an earlier pilot study) and observed data (from this study). We used a mixed-effect modified Poisson regression approach with the site as a random effect to determine the clinical features associated with neuropathology.

Results: MRI abnormalities were found in 140 of 240 (modeled prevalence = 59%, 95% confidence interval [CI]: 53%–64%) of people with epilepsy in Kenya, and in 62 of 91 (modeled prevalence = 65%, 95% CI: 57%–73%) in South Africa, with a pooled modeled prevalence of 61% (95% CI: 56%–66%). Abnormalities were common in those with a history of adverse perinatal events (15/23 [65%, 95% CI: 43%–84%]), exposure to parasitic infections (83/120 [69%, 95% CI: 60%–77%]) and focal electroencephalographic features (97/142 [68%, 95% CI: 60%–76%]), but less frequent in individuals with generalized electroencephalographic features (44/99 [44%, 95% CI: 34%–55%]). Most abnormalities were potentially epileptogenic (167/202, 82%), of which mesial temporal sclerosis (43%) and gliosis (34%) were the most frequent. Abnormalities were associated with co-occurrence of generalized non-convulsive seizures (relative risk [RR] = 1.12, 95% CI: 1.04–1.25), lack of family history of seizures (RR = 0.91, 0.86–0.96), convulsive status epilepticus

This is an open access article under the terms of the [Creative Commons Attribution](https://creativecommons.org/licenses/by/4.0/) License, which permits use, distribution and reproduction in any medium, provided the original work is properly cited.

© 2023 The Authors. *Epilepsia* published by Wiley Periodicals LLC on behalf of International League Against Epilepsy.

Correspondence

Symon M. Kariuki, Neurosciences Unit, KEMRI-Wellcome Trust Research Programme, P O Box 230 (80108) Kilifi, Kenya.

Email: skariuki@kemri-wellcome.org

Funding information

Wellcome Trust, Grant/Award Number: 083744 and 099782/Z/12/Z

(RR = 1.14, 1.08–1.21), frequent seizures (RR = 1.12, 1.04–1.20), and reported use of anti-seizure medication (RR = 1.22, 1.18–1.26).

Significance: MRI identified pathologies are common in people with epilepsy in Kenya and South Africa. Mesial temporal sclerosis, the most common abnormality, may be amenable to surgical correction. MRI may have a diagnostic value in rural Africa, but future longitudinal studies should examine the prognostic role.

KEYWORDS

brain abnormalities, diagnosis, Kenya, mesial temporal sclerosis, South Africa

1 | INTRODUCTION

Epilepsy is a common neurological disorder, with a high prevalence in people from low- and middle-income countries (LMICs) bearing the brunt of the condition.¹ The incidence and prevalence of epilepsy are likely greater in LMICs than in high-income countries (HICs).² The excess burden is due to increased perinatal complications and central nervous system infections.³ Epilepsy with focal features based on semiology and electroencephalography (EEG) is common and was identified in over half of people with convulsive epilepsy in African community surveys.⁴ These focal features represent an identifiable and largely preventable underlying risk for epilepsy, but there is a shortage of neuroimaging studies in LMICs to identify such factors.

The advent of magnetic resonance imaging (MRI) has revolutionized the determination of structural risk factors for epilepsy.⁵ MRI is a high-resource investigation in LMICs, and its use in these settings has been limited to a few studies and case series in tertiary hospitals, mainly in urban settings. A computerized tomography (CT) scan study on Kenyan children with neurological impairments identified in a community survey did not find abnormalities in those with focal impaired awareness seizures.⁶ There were no MRI services available then to validate these findings. Recently, private MRI services have become available in Africa,⁷ offering an opportunity to understand the extent, nature, and pathogenesis of epilepsy in rural and urban areas of Africa. Reliable MRI findings from population-based studies are urgently needed because retrospective audits of visits to private hospitals in urban settings of Africa may not represent epilepsy cases drawn from the community.

The indications for MRI are focal onset epilepsy, unclassifiable generalized epilepsy, especially with onset in the first years of life, and drug-resistant epilepsy.⁸ In LMICs, to increase the yield of abnormalities and ensure cost-effectiveness, this is restricted to epilepsy with focal features/onset and progressive neurological deficits.⁸ The

Key Points

- Focal epilepsy is common in low- and middle-income countries, where the frequency and nature of underlying structural brain abnormalities are not fully assessed.
- Magnetic resonance imaging abnormalities are common in Kenyans and South Africans with epilepsy and are associated with adverse perinatal events and focal electroencephalographic features.
- Mesial temporal sclerosis is prevalent and may be amenable to surgery, especially when unilateral and non-overlapping with other epileptogenic lesions.
- MRI may improve the diagnosis of etiologies in these areas, and the identified abnormalities offer reliable substrates for basing studies on the prognosis of epilepsy in Africa.

prevalence and pattern of MRI abnormalities in epilepsy may differ in LMICs because of the specific risk factors associated with epilepsy.³ Parasitic infections such as malaria cause non-specific lesions,⁹ which may be epileptogenic. Prolonged acute (febrile) seizures, of high prevalence in LMICs,¹⁰ are associated with hippocampal abnormalities,¹¹ which may lead to mesial temporal lobe epilepsy. Perinatal complications are common in Africans with epilepsy and may be associated with cortical and subcortical lesions on MRI.¹² Late-onset epilepsy is common,⁴ but the role of tumors, trauma, and vascular abnormalities is unknown. MRI quickly identifies focal cortical abnormalities, although the frequency among Africans with epilepsy is unknown.

We performed MRI on people with active convulsive epilepsy identified in community surveys undertaken in rural Kenya and South Africa to estimate the extent and describe the nature of preventable and possible treatable

abnormalities. We further examined the relative risks of these abnormalities in individuals with adverse medical histories and neurological comorbidities.

2 | METHODS

2.1 | Study site and participants

This project was coordinated by the KEMRI-Wellcome Trust Research Programme, located in Kilifi Health and Demographic Surveillance System (KHDSS)¹³ and from Agincourt Health and Demographic Surveillance System (AHDSS).¹⁴ The two demographic surveillance systems were part of the five African sites that hosted the Studies of Epilepsy Epidemiology in Demographic sites (SEEDs).³ SEEDs was a three-stage community-based survey, conducted in Ghana, Kenya, South Africa, Tanzania, and Uganda. Screening for seizures in SEEDs was done in the first stage, using two questions, with those screening positive followed up with additional seizure questions in the second stage. Confirmation of epilepsy was done in the third stage through a detailed clinical history.³ The KHDSS is located on the Kenyan coast, and scanning was at the Metropolitan Imaging Centre within Pandya Memorial Hospital in Mombasa. The AHDSS is in a rural, semi-arid area in northeast South Africa close to the Mozambique border. Scanning was performed at MediClinic Imaging Centre in Nelspruit, ~106 km from AHDSS. The two study settings represent populations with limited access to epilepsy services and early interventions for addressing perinatal complications and central nervous system infections.

People with epilepsy were identified in a community survey from December 2007 to February 2009. MRI scans were performed from February 2010 to July 2013 in Agincourt, South Africa, and between March 2013 and May 2016 in Kilifi, Kenya, depending on the space availability at the imaging centers. The youngest age of recruitment was 3 years in South Africa and 5 years in Kenya. We scanned people with epilepsy in distinct risk groups that could have been mutually exclusive, each selected randomly from a database of people with epilepsy. The focal epilepsy group comprised 142 people with localized EEG features (described below) whose MRI abnormalities were compared to 99 scans from people with generalized epilepsy and 23 from people with epilepsy and a history of adverse perinatal events. We also performed MRI scans on 120 people with epilepsy and confirmed exposure to parasitic infections, overlapping with the above groups; a detailed analysis will be presented in a separate report (Figure S1). Exposure to parasitic and viral infections was confirmed through the presence of antibodies in blood as described previously.¹⁵

Clinical, neurological and electroencephalographic features of active convulsive epilepsy have been described previously.⁴ We defined active epilepsy as a history of at least two unprovoked seizures, with one seizure in the previous 12 months.¹⁶ Focal EEG features were defined as localized abnormal EEG patterns involving one or more discrete regions of the brain.¹⁷ Focal epilepsy was defined as those with focal seizure semiology and focal epileptiform discharges on EEG. Generalized epilepsy was defined as those with generalized seizure semiology and/or generalized epileptiform discharges on EEG.⁴ Adverse perinatal events were defined as delays in crying, breathing, and initiation of breastfeeding after birth. Seizure classification was based on the pragmatic International League Against Epilepsy (ILAE) recommendations as used in previous studies.¹⁸ Status epilepticus was defined as seizures lasting for 30 min or more.¹⁹ A clinician assessed cognitive impairment by asking the individual standardized questions about person, place, and time, and incorrect responses to any or all of the three questions were considered impaired. Daily seizures were considered frequent, and those occurring weekly, monthly, or yearly were considered less frequent. The prevalence of the four most common infections ranged from 40% to 76% for *Plasmodium falciparum*, 6%–19% for HIV, 10%–42% for *Toxocara canis*, and 12%–32% for *Toxoplasma gondii*, in those with active convulsive epilepsy across the two sites.

2.2 | Procedures for MRI scans

Eligible individuals reported to an agreed collection point within each health and demographic surveillance system or were collected from home. Participants in both sites were escorted to the MRI centers and could attend with a relative or caretaker.

The scanner at the Metropolitan MRI center in Kenya was a Signa HDe 1.5 Tesla, General Electric, whereas in Mbombela, South Africa, it was a Philips Achieva 1.5 Tesla A-series. These epilepsy protocols were available in both centers: axial turbo-spin-echo (TSE) transverse relaxation time (T2), coronal TSE T2, coronal T2 map, coronal fluid-attenuated inversion recovery (FLAIR), apparent diffusion coefficient (ADC) and three-dimensional (3D) FLAIR. Sagittal magnetization-prepared rapid grad echo (MPrage)-3D-volume and fast low angle shot (FLASH) longitudinal relaxation time (T1) 3D were available only in South Africa, and coronal 3D T1 only in Kenya. As per recommendations, we used standard partition sizes (≤ 3 mm) in the sequences.⁸ In South Africa, contrast was used if the scan was clinically suggestive of pathologies

such as arteriovenous brain malformations, but this was not available in Kenya.

R.G. and F.D. (consultant neuroradiologists) reported the scans including classification of abnormalities while blinded to the participant's status. For instance, a clinical history of a head injury would support post-traumatic gliosis/encephalomalacia but not post-infective gliosis/encephalomalacia. R.G. read the first 243 scans from Kenya and South Africa, and F.D. read the remaining 88 from Kenya only. We broadly categorized abnormal MRI scans into epileptogenic (mesial temporal sclerosis [bilateral or unilateral involvement of hippocampus], gliosis or encephalomalacia [related to infections, trauma, or unspecified causes], developmental abnormalities [focal cortical dysplasia, toxoplasmosis, other infections (eg HIV, syphilis and hepatitis B), rubella, cytomegalovirus and herpes simplex (TORCH)-related lesions, nodular heterotopia, polymicrogyria, and perinatal ischemic lesions], vascular anomalies [related to small vessel ischemia, cerebral arteries, or unspecified causes], and tumors [dysembryoplastic neuroepithelial tumors (DNETs) and gangliomas]) and non-epileptogenic (non-specific white matter lesions, hippocampal signal changes/swelling, and cerebral atrophy or volume loss). Localization of abnormalities to lobes or other regions, for example, periventricular areas, corpus callosum, cerebellum and brainstem, was determined. The timing of abnormalities was presumed to be prenatal if they involved border zones of the cerebral arteries, perinatal if they affected parasagittal and periventricular watershed territories, and postnatal if they were in other hemispheric regions.^{20,21} We defined epileptogenic lesions as those likely to precipitate seizures.²²

2.3 | Statistical analysis

There were no MRI studies of people with epilepsy in LMICs during the study design phase, and we based our power estimations on an Australian study. In this study, the prevalence of abnormalities in focal epilepsy was 53%.²² We estimated that to detect MRI abnormalities with a precision of 5%, we would have to scan at least 148 individuals selected from 240 people with epilepsy with focal EEG features (as our sampling frame).

We performed data analysis in Stata (Version 11, StataCorp, College Station, TX) and R statistical software (version 4.0.0 (2020-04-24)—“Arbor Day”). Based upon the sampling, an estimate of the prevalence of potentially epileptogenic abnormalities was modeled in R. We used beta distribution (21, 31) of priors from a previous MRI study of 50 people with epilepsy. Using empirical

estimates from this study, and when necessary, adjusting for the sensitivity of the methodology used to identify epilepsy cases. We used a mixed-effect modified Poisson regression approach with the site as a random effect, a log-link function and a robust error variance to estimate the modifiable relative risks of MRI abnormalities in a penultimate model of the entire sample (adjusted for age, sex, epilepsy group, education, and marital status of parents) and a final model of the whole sample (penultimate model above additionally adjusted for the four phenotypic/study groups [focal EEG features, generalized EEG features, adverse perinatal events, and infections]). The distribution of MRI abnormalities was provided as percentages, and comparisons were made with Pearson's chi-square test between groups. The rate of MRI abnormalities was extrapolated to the number of epilepsy cases identified from the primary community survey,³ which were divided by the general population in the study area to estimate the overall prevalence of MRI abnormalities, adjusting for the sensitivity of the screening tool in the survey. Continuous variables (e.g., age) were compared between groups using the Mann-Whitney test. The level of significance was set at $p < .05$.

2.4 | Standard protocol approvals, registrations, and consents

The National Ethical Review body approved this project in Kenya (SSC No 2428). In South Africa, the study was approved by the University of the Witwatersrand's Human Research Ethics Committee (Medical) South Africa (M080455) and the Mpumalanga Province Health Research Ethics Committee. Participants or caregivers provided written informed consent to take part in the study.

3 | RESULTS

We scanned 331 people (Figure S1), of whom 165 (50%) were male, and the median age was 18.5 years (range, 3.0–89.0) (Table 1). The overlapping distribution of the participants according to the four clinical groups—focal EEG features, exposure to infections, generalized EEG features, and perinatal events—are presented in Figure 1. Compared to those from Kenya, South African participants were older, had a later onset of seizures, and had experienced fewer adverse perinatal events, hospitalizations, and febrile seizures in the past (Table 1). There were no statistically significant differences between those who underwent MRI and those who were

TABLE 1 Characteristics of study participants with active convulsive epilepsy.

Characteristics	Agincourt, South Africa (N=91)	Kilifi, Kenya (N=240)	Both sites (N=331)	p-value
Age (IQR) in years	31.0 (18.0–46.0)	14.0 (7.0–24.0)	18.5 (10.0–35.0)	<.0001
Male sex	48 (53%)	118 (49%)	166 (50%)	.561
Age at onset of seizures (IQR) in years	13.0 (3.7–29.7)	2.5 (1.0–10.0)	3.3 (1.0–13.2)	<.0001
Medical history				
Family history of any seizures	4/86 (5%)	59/235 (25%)	63/312 (20%)	<.0001
History of febrile seizures	1/90 (1%)	35/227 (15%)	36/317 (11%)	<.0001
Previous hospitalization	23/89 (26%)	155/237 (65%)	178/326 (54%)	<.0001
History of acute encephalopathy	3/89 (3%)	65/226 (29%)	68/315 (22%)	<.0001
Study groups				
Focal EEG features	56 (61%)	86 (35%)	142 (43%)	<.0001
Adverse perinatal events	3 (3%)	20 (8%)	23 (7%)	.108
Generalized EEG features	3 (3%)	96 (40%)	99 (30%)	<.0001
Seizure types, ASM use, and convulsive status epilepticus				
Focal convulsive	42 (46%)	137 (57%)	179 (54%)	.075
Focal non-convulsive	4 (4%)	33 (14%)	37 (11.0%)	.018
Generalized convulsive	50 (55%)	68 (28%)	118 (36%)	<.0001
Generalized non-convulsive	7 (8%)	10 (4%)	17 (5%)	.194
Reported ASM use	54 (59%)	109 (45%)	163 (49%)	.024
Convulsive status epilepticus	29/86 (34%)	83/223 (39%)	115/309 (37%)	.430
Neurological and medical comorbidities				
Neurological deficits	15/89 (17%)	38/237 (16%)	53/326 (16%)	.858
Cognitive impairments	21/89 (24%)	53/237 (22%)	74/326 (23%)	.813
Burns	14/89 (16%)	42/236 (18%)	56/325 (17%)	.660

Abbreviations: ASM, anti-seizure medication; EEG, electroencephalography.

not selected for male sex (50% vs 49%; $p = .704$), being a child (53% vs 57%; $p = .188$), and unemployment status (39% vs 35%; $p = .124$).

3.1 | The overall frequency of MRI abnormalities

We identified MRI abnormalities in 140 of 240 (58%) of those in Kilifi and 62 of 91 (68%) in Agincourt, providing a modeled pooled prevalence of 61% (95% confidence interval [CI]: 56%–66%); $I^2 = 63\%$. These abnormalities occurred more frequently in adults than children (73% vs 50%; $p < .0001$). Abnormalities were present in 97 of 142 (66%, 95% CI: 60%–76%) of those with focal EEG features, 83 of 120 (69%, 95% CI: 60%–77%) of those with infections, 15 of 23 (65%) of those with perinatal complications, and 44 of 99 (44%, 95% CI: 34%–55%) of those with generalized epilepsy on semiology and EEG. The unadjusted population-based prevalence of MRI abnormalities was 2.1 per 1000 (95% CI: 1.9–2.3) with the adjusted prevalence being 4.3 per 1000 (95% CI: 3.9–4.7).

3.2 | Localization and timing of abnormalities

Of the 202 abnormalities, 98 (49%) involved both hemispheres. Localization of these abnormalities to a region of the brain was possible for 193 of the 202 abnormalities, most of which were in the temporal lobes (138, 72%) and frontal lobes (107, 55%) (Table S1). Timing of a brain insult could be established in 161 (80%): 54 of 62 (87%) in Agincourt and 107 of 140 (76%) in Kilifi. Abnormalities occurred prenatally in 14 (7%), perinatally in 49 (24%), and postnatally in 116 (57%), with onset of some postnatal abnormalities beginning at perinatal (38%) and prenatal (14%) periods.

3.3 | Types of MRI abnormalities

Of the 202 abnormalities, 167 (83%) were potentially epileptogenic (comprising tumors, gliosis/encephalomalacia, developmental, and vascular-related lesions) with a similar distribution in Kilifi (84%) and Agincourt

N = 331

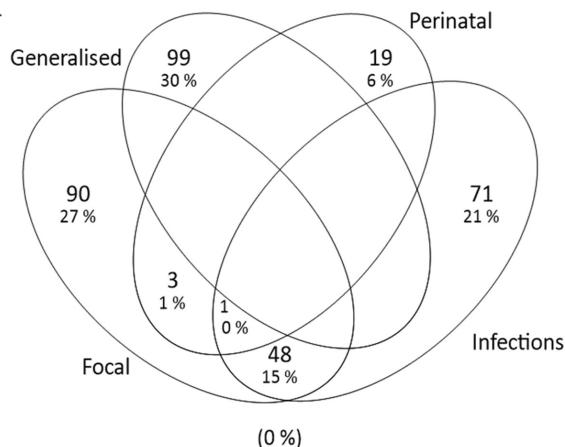


FIGURE 1 Overlap of participants by phenotypes. Participants are distributed across focal electroencephalographic features, generalized electroencephalographic features, adverse perinatal events, and exposure to infections, which were not mutually exclusive.

(79%) ($p = .363$). Cerebral volume loss/atrophy, a non-epileptogenic lesion, was reported in 68 of 202 (34%) of those with at least one abnormality (Table 2) and was significantly more common in Kilifi (58/140, 41%) than in Agincourt (10/62, 10%) ($p < .0001$). Atrophy was also more frequent in those with a history of previous hospitalization (45/109 [41%] vs 22/91 [28%]; $p = .011$), and treatment for infective encephalopathy (25/48 [52%] vs 41/148 [28%]; $p = .002$).

Mesial temporal sclerosis (MTS) was the most common abnormality, occurring in 73 of 331 (22%), with a similar prevalence in Kilifi (57/240, 24%) and Agincourt (16/91, 18%; $p = .258$) (Table 2). MTS were identified more in adults than children (28% vs 16%; $p = .011$). MTS accounted for over one-third of abnormalities (73/202, 36%) and almost half of the majority of the epileptogenic lesion 73 of 168 (43%). Most MTS were unilateral (59/73, 81%) (Figure 2) and were more common in those with focal EEG features (39/142, 27%) and infections (29/120, 24%) (Table 2). Of 42 of 73 (58%) of MTS cases not overlapping with other epileptogenic lesions, 31 (74%) were unilateral, and the remainder were bilateral. MRI abnormalities were distributed similarly in frequent seizures (36% vs 36%; $p = .981$) and status epilepticus (40% vs 33%; $p = .328$).

Gliosis/encephalomalacia was found in 57 of /331 (28%) of all those scanned (Figure 2), with the occurrence being significantly higher in Kilifi (47/140, 34%) than in Agincourt (10/62, 16%) ($p = .011$). Gliosis/encephalomalacia was more common in children than adults (38% vs 18%; $p = .002$). These abnormalities were more common in those with adverse perinatal events (4/23, 17%) and generalized EEG features (22/99, 22%) (Table 2). Among those

TABLE 2 Frequency of epileptogenic and non-epileptogenic MRI abnormalities according to selection criteria.

Abnormality	Focal EEG features		Infections		Adverse perinatal events		Generalized EEG features	
	Agincourt: N = 56	Kilifi: N = 86	Agincourt: N = 60	Kilifi: N = 60	Agincourt: N = 3	Kilifi: N = 20	Agincourt: N = 3	Kilifi: N = 96
Mesial temporal sclerosis	12 (21%)	27 (31%)	10 (17%)	19 (32%)	0	3 (15%)	0	14 (15%)
Gliosis/encephalomalacia	3 (5%)	17 (20%)	9 (15%)	8 (13%)	0	4 (20)	0	22 (23%)
Perinatal/developmental lesions	9 (16%)	10 (12%)	8 (13%)	7 (12%)	0	7 (35%)	1 (25%)	8 (8%)
Vascular anomalies	9 (16%)	4 (5%)	11 (18%)	5 (8%)	0	4 (20%)	0	14 (15%)
Tumor: DNET/ganglioglioma	1 (2%)	1 (2%)	0	0	0	0	1 (33%)	1 (1%)
Non-epileptogenic lesions	2 (4%)	6 (7%)	8 (13%)	6 (10%)	0	2 (10%)	0	5 (5%)

Note: Numbers may not be mutually exclusive when phenotypic groups overlap.

Abbreviations: EEG, electroencephalography; DNET, disemryoplastic neuroepithelial tumor; focal (localized abnormalities involving a region of the brain) EEG features.

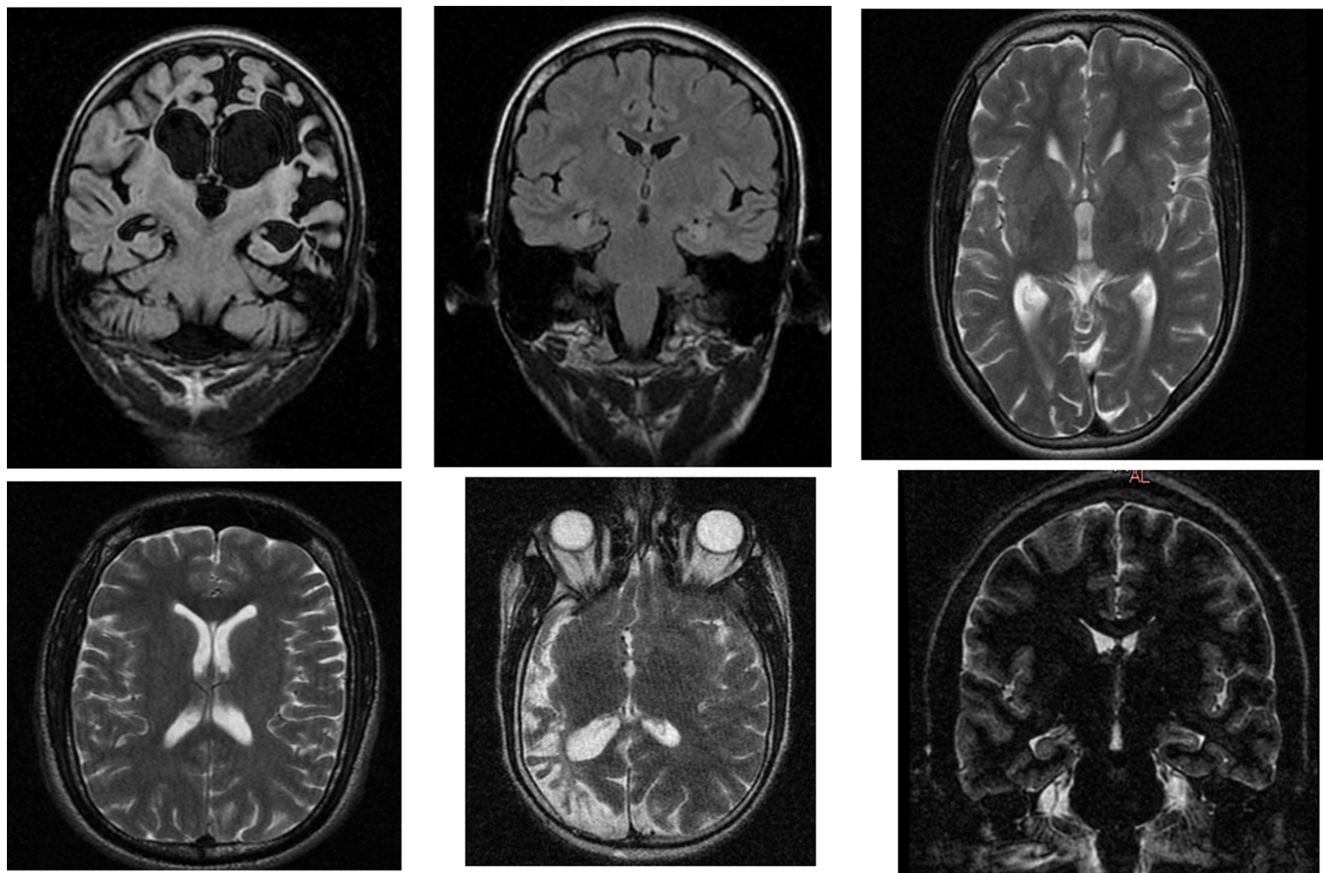


FIGURE 2 Types of magnetic resonance imaging (MRI) abnormalities. First row, left to right: hypox-i-ischemic encephalopathy (HIE) at term and bilateral mesial temporal sclerosis (MTS) in an 8-year-old girl; mild generalized cerebral atrophy in a 17-year-old boy and bilateral MTS in a 29-year-old woman. Second row, left to right: Normal scan in a 25-year-old man and encephalomalacia in an 18-year-old woman, and left MTS coronal T2 in an 18-year-old man.

with abnormalities, most had a history of previous head injury (7/16 [44%] vs 28/150 [18%]; $p=.003$) and or admission with an infective encephalopathy (18/48 [38%] vs 37/148 [25%]; $p=.094$).

Developmental abnormalities occurred in 42 of 331 (13%) of all scanned participants; similar in Agincourt (13/91, 14%) and Kilifi (29/240, 12%); $p=.591$). They were more common in those with adverse perinatal events (7/23, 30%) and focal EEG features (19/142, 13%) (Table 2). Among those with an abnormality, those with developmental malformations had a similar history of abnormal pregnancy (4/15 [27%] vs 15/65 [23%]; $p=.768$). Vascular abnormalities were reported in 16 of 331 (11%), being similar in Agincourt (12/91, 13%) and Kilifi (24/240, 10%); $p=.406$). These abnormalities were most common in those adverse perinatal events (4/23, 17%) and generalized EEG features (14/99, 14%) (Table 2). Tumors were seen in 3 of 331 (1%), all in adults in Agincourt (2/91, 1%) and Kilifi (1/240, 0.5%).

Non-epileptogenic abnormalities (cerebral and cerebellar atrophy, hippocampal swelling and signal changes, and non-specific white matter lesions) occurred in

relatively low frequencies across the clinical groups studied (Table 2).

3.4 | Association of MRI abnormalities with epilepsy factors, medical history, and comorbidities

Factors particularly associated with MRI abnormalities in adjusted models were: generalized non-convulsive seizures (relative risk [RR]=1.12, 95% CI: 1.04–1.20), frequent seizures (RR=1.28, 1.18–1.39), reported use of antiseizure medication (ASM; RR=1.22, 1.18–1.26), family history of seizures (RR=0.91, 0.86–0.96), and convulsive status epilepticus (RR=1.14, 1.08–1.21) (Table 3).

4 | DISCUSSION

We describe the frequency and nature of brain abnormalities detected in people with epilepsy in Kenya and South Africa. We identified anomalies in over 60% of the

TABLE 3 Distribution of MRI abnormalities according to presence of antibody titers, seizure types, status epilepticus, use of antiseizure medication (ASM), and medical comorbidities.

Clinical feature	MRI normal (N = 202)	MRI abnormal (N = 129)	Adjusted model 1		Adjusted model 2	
			RR (95% CI)	p-value	RR (95% CI)	p-value
Epilepsy-related factors						
Age at onset of seizures (IQR), years	3.3 (1.7–11.3)	3.3 (0.9–16.4)	0.98 (0.99–1.00)	.044	0.99 (0.98–1.00)	.174
Focal convulsive seizures	57 (44%)	122 (60%)	1.02 (0.94–1.11)	.517	1.03 (0.97–1.10)	.236
Focal non-convulsive seizures	17 (13%)	20 (10%)	0.74 (0.30–1.80)	.432	0.78 (0.32–1.88)	.540
Generalized convulsive seizures	51 (40%)	67 (33%)	1.03 (1.01–1.06)	.007	1.00 (0.97–1.03)	.855
Generalized non-convulsive seizures	9 (7%)	8 (4%)	1.13 (1.10–1.16)	.009	1.12 (1.04–1.20)	<.0001
Frequent daily seizures	8 (6)	22 (11%)	1.33 (1.23–1.44)	<.0001	1.28 (1.18–1.39)	<.0001
Reported use of ASMs	44 (34%)	119/195 (59%)	1.19 (1.18–1.20)	<.0001	1.22 (1.18–1.26)	<.0001
Medical history and comorbidities						
Family history of any seizure	29/124 (23%)	34/197 (17%)	0.92 (0.90–0.94)	<.0001	0.91 (0.86–0.96)	<.0001
History of acute encephalopathy	20/119 (17%)	48/196 (24%)	1.09 (1.02–1.16)	.010	1.10 (0.94–1.28)	.220
All head injuries	6/80 (8%)	16/166 (10%)	0.96 (0.72–1.29)	.837	0.981 (0.74–1.31)	.942
Status epilepticus	38/118 (32%)	77/191 (40%)	1.15 (1.01–1.31)	.034	1.14 (1.08–1.21)	<.0001
Neurological deficits	9/126 (7%)	44/200 (22%)	1.13 (1.10–1.36)	.246	1.14 (0.92–1.41)	.207
Intellectual disability	14/126 (11%)	60/200 (30%)	1.00 (0.65–1.55)	.967	1.00 (0.61–1.62)	.999
Malnutrition	23/126 (18%)	29/196 (15%)	0.99 (0.64–1.53)	.969	0.99 (0.63–1.57)	.993

Note: ASM, anti-seizure medication; CI, confidence interval; IQR, interquartile range; both modified Poisson models had site entered as a random effect; adjusting for age, sex, and parental education, marital prospects, and employment status; Additionally, adjusted for the four phenotypic groups.

participants, and the overall adjusted prevalence shows that these are relatively common in the community. Most abnormalities were localized in the mesial temporal lobes, particularly epileptogenic. Over 80% of all lesions were potentially epileptogenic, with MTS occurring in over one-third, constituting one-fifth of all people scanned. Gliosis/encephalomalacia and developmental lesions were common, particularly those with adverse perinatal events and focal EEG features. The relative risk of MRI abnormalities was significantly increased in those with non-convulsive seizures (in addition to convulsive seizures) and status epilepticus. The risk decreased with a family history of seizures, likely to be partly a proxy for genetic susceptibility.

4.1 | Diagnostic yield of MRI

The diagnostic yield of MRI in sites was high, identifying structural abnormalities in two-thirds of people with epilepsy who had focal semiology or EEG abnormalities. These yields were exceptionally high in those with focal EEG features, which we previously proposed represent identifiable and potentially preventable lesions.^{4,23} The estimates of abnormalities in our study (61%) are similar to those reported in rural China (65%).²⁴ There are, however, notable differences between the two studies. For instance,

we preselected participants according to risk groups, including those with generalized seizures and EEG features in whom the yield of abnormalities would be lower. The Chinese study also included people with well-controlled seizures and for whom adherence could be determined. This would be challenging in Africa, where access to epilepsy services is poor and a significant treatment gap exists. The prevalence of abnormalities is also comparable with studies from Western countries but more significant than in those that included newly diagnosed epilepsy (20%–50%).^{22,25} It distinguished localized from generalized abnormalities, confirming that most epilepsy in Africa may be lesional. The timing of abnormalities could be traced to the postnatal period in under two-thirds. Still, these overlapped substantially with prenatal and perinatal periods, when the development of some of these abnormalities may have been initiated. The preponderance of abnormalities in adults may be a proxy for the deterioration of epilepsy with time, further increasing the risk for cerebral atrophy.²⁶

MRI abnormalities were highest in people with focal EEG abnormalities and a history of exposure to central nervous system (CNS) parasitic infections, which are thought to be important markers of localized potentially epileptic disturbance in this region. Although EEG features are reliable biomarkers for brain damage, infection

markers in the blood may be a measure of exposure rather than a risk for epilepsy. MRI may have a diagnostic value in those with a history of neonatal insults, and otherwise normal EEG, since abnormalities were found in over two-thirds. Studies in HICs have identified abnormalities in proportions similar to ours among people with epilepsy but otherwise normal EEG.^{22,25} The finding that abnormalities were common with generalized EEG features may suggest that MRI investigations in people with generalized epilepsy are justified, for whom not every lesion observed would represent a pathologic substrate for epilepsy and those with generalized epilepsy due to structural causes. Some of the generalized EEG abnormalities may have started as focal with rapid generalization that could not be easily determined during interpretation. An Indian study classified epilepsy with generalized seizures into presumed genetic epilepsy in 29% and structural/metabolic epilepsy in 13%.²⁷ The presence of more abnormalities in generalized epilepsy in our study than in India may suggest that the risk factors for neurological damage are more common in our settings, particularly brain infections.

4.2 | Potential epileptogenic lesions

MTS, gliosis/encephalomalacia, and developmental lesions were the most common abnormalities. Higher reports of MTS in children are consistent with other studies that partly attribute this to late limbic system maturation.²⁸ The high proportion of MTS seen in both sites is crucial. It was associated with a history of infective encephalopathy in our study and prolonged febrile seizures in another study.¹¹ Infections of the brain, such as malaria, cause prolonged seizures but can be controlled through treatment. Notably, most unilateral lesions were in the temporal lobe, where MTS may be associated with severe neurocognitive and psychiatric comorbidities, which could partly explain the neuropsychiatric comorbidity previously reported.²⁹ MTS may be a marker of pharmacoresistant epilepsy, but this can be difficult to establish in resource-poor settings, where new-generation ASMs are not readily available. MTS is amenable to curative surgery if concordant with seizure onset and eloquent brain areas are spared. Seizure freedom is better following resection for MTS (60%–90%) than for other focal epilepsies (40%–70%).³⁰ Most of the MTS in our sample were unilateral (80%), with about one-third showing no overlap with other epilepsy and so could benefit from surgery. However, most facilities in Africa are under-resourced for epilepsy surgery evaluation and procedures.³¹ The lateralization of hippocampal sclerosis was more on the left than right, similar to other studies.³² Still, the reason for this differential occurrence is not fully understood. Some epilepsy risk factors may have an affinity

for one side over another, for example, a history of febrile seizures for those with right MTS.³³ Most gliosis was due to infections or trauma, with both previously documented in Africans with epilepsy.⁴ The pathogenesis of gliosis, which was more common in children than in adults, has been linked to cerebral malaria.^{34,35} Lesions from acute pediatric cerebral malaria have a preference for the white matter as opposed to basal ganglia in adults.³⁶ These MRI estimates are higher than those of CT scan studies, which is attributable to the relatively high sensitivity of MRI over CT scans in identifying cerebral abnormalities. Varying the sensitivity or specificity of MRI from hypothetical values of 50–100 in Bayesian inference models did not appear to affect the prevalence estimates (findings not provided in this report).

Developmental abnormalities, particularly those caused by hypoxic–ischemic encephalopathy, were common, confirming perinatal complications as significant risk factors for epilepsy in Africa.^{3,37} The presence of few vascular abnormalities suggests that conditions compromising the integrity of brain vessels, for example, infections possibly in Kilifi or old-age degeneration possibly in Agincourt can be proximate causes of epilepsy in Africa.⁴

Tumors were infrequent, despite there being generally older participants and better volume acquisition protocols in South Africa. Brain tumors may be less frequent in younger populations,³⁸ but it is unclear if their low yield in our samples (with adults well represented) is due to a lack of contrasted imaging. All three were classified as possible DNETs frequently seen in young adults as the participants in our study.

4.3 | The relative risk of MRI abnormalities

The increased risk of MRI abnormalities in those with frequent seizures, status epilepticus, and generalized non-convulsive seizures supports the hypothesis that neuropathologies are a marker of severe epilepsy and can influence the decision to seek treatment in Africa.³⁹ Similar to this study, an Australian report also found that MRI lesions predicted a decision to seek treatment for epilepsy.²² MRI lesions were associated with neurocognitive deficits, suggesting that they are reliable substrates for prognostic studies, similar to previous studies of surgical candidates.⁴⁰

4.4 | Non-epileptogenic lesions

Non-epileptogenic abnormalities were relatively uncommon, with non-specific white matter lesions and

volume loss or atrophy being the most salient. These are possible consequences of poorly controlled seizures,⁴¹ as our study supported a near-significant association between atrophy and frequent seizures. These, however, could be prevented by reducing the epilepsy treatment gaps documented in African countries.^{42,43} The non-specific white matter lesions may also indicate ubiquitous exposure to intracranial infections, particularly falciparum malaria endemic in Kilifi and HIV endemic in Agincourt. Continuous exposure to infection after the onset of epilepsy may determine the clinical phenotype,⁴⁴ including radiographic features.

4.5 | Strengths and limitations

We estimate potential epileptogenic abnormalities and the nature of abnormalities that underlie epilepsy in community surveys in rural Africa and compare the data from two countries. However, the two sites have diversities in ecology, culture, and ethnicity, differences that could not be addressed adequately with the statistical models used. These results could be applied to other African countries with similar ecological, cultural, and sociodemographic settings. This study used 1.5 Tesla scanners, which may miss some lesions, and we could not perform functional imaging or positron emission tomography on those with negative scans for logistical reasons. Discrepancies in interpretations between the two neuroradiologists would have been minimal because similar standardized interpretation criteria were followed. It was difficult to rule out abnormalities that may have occurred between the identification of epilepsy cases and the recording of MRI scans. Use of mutually exclusive phenotypic groups may reduce the power to examine the relative excess risk of interaction for abnormalities. These results are based on single scans, and the yield may increase with serial follow-up scans and contrast.

5 | CONCLUSIONS

MRI abnormalities are common in Africans with epilepsy and are associated with adverse perinatal events and focal EEG features. The frequency of abnormalities is comparable to that of new-onset and intractable epilepsy studies in HICs. MTS is particularly common and may be amenable to surgery. MRI may improve the diagnosis of the cause of epilepsy in this area, and the identified abnormalities offer reliable substrates for basing studies on the prognosis of epilepsy in Africa. Further studies are required to understand the role of infections in MRI abnormalities and to compare these findings with other LMIC settings.

AUTHOR CONTRIBUTIONS

S.K., R.G.W., H.J.C., S.W., J.W.S., and C.N. conceptualized and designed the study. S.K., C.N., R.G.W., and M.K. helped obtain the neuroimaging scans; R.G., F.D., and H.J.C. interpreted the scans with the support of S.K. and C.N. S.K., A.K.N., R.O., and C.N. were responsible for data management, analysis, and choosing data-visualization methods. S.K. wrote the initial draft with the support of C.N. All authors provided feedback on the initial draft via comments and suggestions and approved the manuscript for publication.

ACKNOWLEDGMENTS

This study was supported by the Wellcome Trust through a senior research fellowship (083744) to C.N. and Research Training Fellowship (099782/Z/12/Z) to S.K., who is also supported by MQ: Transforming Mental Health (MQF17-18) and by the EDCTP2 Programme funded by the European Union (TMA2017CDF-1903). The MRC/Wits Rural Public Health and Health Transitions Research Unit and Agincourt Health and Socio-Demographic Surveillance System, a node of the South African Population Research Infrastructure Network (SAPRIN), is supported by the Department of Science and Innovation, the University of the Witwatersrand, and the Medical Research Council, South Africa, and previously the Wellcome Trust, UK (grants 058893/Z/99/A; 069683/Z/02/Z; 085477/Z/08/Z; 085477/B/08/Z). R.G.W. is supported by the South African National Research Foundation (119234). J.W.S. is based at UCLH/UCL Comprehensive Biomedical Research Centre, which receives a proportion of funding from the UK Department of Health's NIHR Biomedical Research Centres funding scheme. He receives support from the Dr Marvin Weil Epilepsy Research Fund, the Christelijke Vereniging voor de verpleging van Lijders aan Epilepsie, The Netherlands, and the UK Epilepsy Society. We are grateful to Dr Giacomo Talenti for help with the interpretation of some of the MRI scans. This paper is published with the permission of the director of KEMRI.

CONFLICT OF INTEREST STATEMENT

J.W.S. received consultancies from UCB and Arvelle; grants from UCB; and payment for serving on speakers' bureaus from GW, Arvelle, Eisai, UCB, Novartis outside this work. The other authors report no disclosures.

ORCID

Symon M. Kariuki  <https://orcid.org/0000-0002-3934-5132>

Ryan G. Wagner  <https://orcid.org/0000-0003-2741-3676>

Felice D'Arco  <https://orcid.org/0000-0001-7396-591X>

J. Helen Cross  <https://orcid.org/0000-0001-7345-4829>

Josemir W. Sander  <https://orcid.org/0000-0001-6041-9661>

REFERENCES

- Ngugi AK, Bottomley C, Kleinschmidt I, Sander JW, Newton CR. Estimation of the burden of active and life-time epilepsy: a meta-analytic approach. *Epilepsia*. 2010;51:883–90.
- Newton CR, Garcia HH. Epilepsy in poor regions of the world. *Lancet*. 2012;29(380):1193–201.
- Ngugi AK, Bottomley C, Kleinschmidt I, Wagner RG, Kakooza-Mwesige A, Ae-Ngibise K, et al. Prevalence of active convulsive epilepsy in sub-saharan africa and associated risk factors: cross-sectional and case-control studies. *Lancet Neurol*. 2013;12:253–63.
- Kariuki SM, Matuja W, Akpalu A, Kakooza-Mwesige A, Chabi M, Wagner RG, et al. Clinical features, proximate causes, and consequences of active convulsive epilepsy in Africa. *Epilepsia*. 2014;55(1):76–85.
- Duncan JS. Imaging and epilepsy. *Brain*. 1997;120(2):339–77.
- Njuguna PW, Mungala-Odera V, Chong WK, Meehan RA, Newton CR. Computerized tomography scan of the brain in a community study of neurological impairment in Kenya. *J Child Neurol*. 2007;22:26–32.
- Samia P, Odero N, Njoroge M, Ochieng S, Mavuti J, Waa S, et al. Magnetic resonance imaging findings in childhood epilepsy at a tertiary hospital in Kenya. *Front Neurol*. 2021;12:623960.
- ILAE. Recommendations for neuroimaging of patients with epilepsy. *Epilepsia*. 1997;38:1255–6.
- Potchen MJ, Kampondeni SD, Seydel KB, Birbeck GL, Hammond CA, Bradley WG, et al. Acute brain MRI findings in 120 Malawian children with cerebral malaria: new insights into an ancient disease. *Am J Neuroradiol*. 2012;33:1740–6.
- Kariuki SM, Abubakar A, Kombe M, Kazungu M, Odhiambo R, Stein A, et al. Prevalence, risk factors and behavioural and emotional comorbidity of acute seizures in young Kenyan children: a population-based study. *BMC Med*. 2018;16(1):1–2.
- Shinnar S, Bello JA, Chan S, Hesdorffer DC, Lewis DV, Macfall J, et al. MRI abnormalities following febrile status epilepticus in children: the FEBSTAT study. *Neurol*. 2012;79(9):871–7.
- Rutherford M, Biarge MM, Allsop J, Counsell S, Cowan F. MRI of perinatal brain injury. *Pediatric Radiol*. 2010;40:819–33.
- Scott JAG, Bauni E, Moisi JC, Ojal J, Gatakaa H, Nyundo C, et al. Profile: the Kilifi health and demographic surveillance system (KHDSS). *Int J Epidemiol*. 2012;41:650–7.
- Kahn K, Collinson MA, Gomez-Olive FX, Mokoena O, Twine R, Mee P, et al. Profile: agincourt health and socio-demographic surveillance system. *Int J Epidemiol*. 2012;41:988–1001.
- Kamuyu G, Bottomley C, Mageto J, Lowe B, Wilkins PP, Noh JC, et al. Exposure to multiple parasites is associated with the prevalence of active convulsive epilepsy in sub-Saharan Africa. *PLoS Negl Tropic Dis*. 2014;8:e2908.
- ILAE. Proposal for revised classification of epilepsies and epileptic syndromes. *Epilepsia*. 1989;30:389–99.
- Kariuki SM, White S, Chengo E, Wagner RG, Ae-Ngibise KA, Kakooza-Mwesige A, et al. Electroencephalographic features of convulsive epilepsy in Africa: a multicentre study of prevalence, pattern and associated factors. *Clin Neurophysiol*. 2016;127(2):1099–107.
- Thurman DJ, Beghi E, Begley CE, Berg AT, Buchhalter JR, Ding D, et al. Standards for epidemiologic studies and surveillance of epilepsy. *Epilepsia*. 2011;52:2–26.
- Newton CR, Kariuki SM. Status epilepticus in sub-Saharan Africa: new findings. *Epilepsia*. 2013;54(Suppl 6):50–3.
- Varghese B, Xavier R, Manoj VC, Aneesh MK, Priya PS, Kumar A, et al. Magnetic resonance imaging spectrum of perinatal hypoxic-ischemic brain injury Indian. *J Radiol Imaging*. 2016;26:316–27.
- Teixeira RA, Zanardi VA, Li LM, Santos SLM, Cendes F. Epilepsy and destructive brain insults in early life: a topographical classification on the basis of MRI findings. *Seizure*. 2004;13:383–91.
- Hakami T, McIntosh A, Todaro M, Lui E, Yerra R, Tan KM, et al. MRI-identified pathology in adults with new-onset seizures. *Neurology*. 2013;3(81):920–7.
- Munyoki G, Edwards T, White S, Kwasa T, Chengo E, Kokwaro G, et al. Clinical and neurophysiologic features of active convulsive epilepsy in rural Kenya: a population-based study. *Epilepsia*. 2010;51:2370–6.
- Davagnanam I, Chen Z, Hoskote C, Ding D, Yang B, Wang Y, et al. Prevalence of MRI abnormalities in people with epilepsy in rural China. *Neurology*. 2020;95:e1236–43.
- King MA, Newton MR, Jackson GD, Fitt GJ, Mitchell LA, Silvapulle MJ, et al. Epileptology of the first-seizure presentation: a clinical, electroencephalographic, and magnetic resonance imaging study of 300 consecutive patients. *Lancet*. 1998;352:1007–11.
- Ibdali M, Hadjivassiliou M, Grünewald RA, Shanmugarajah PD. Cerebellar degeneration in epilepsy: a systematic review. *Int J Environ Res Public Health*. 2021;18:473.
- Singh G, Singhal S, Sharma S, Paul BS, Bansal N, Chaudhary A, et al. Clinical characteristics of epilepsy in resource-limited communities in Punjab. *Northwest India Epilepsia Open*. 2020;5:582–95.
- Fontana E, Negrini F, Francione S, Mai R, Osanni E, Menna E, et al. Temporal lobe epilepsy in children: electroclinical study of 77 cases. *Epilepsia*. 2006;47:26–30.
- Mwangala PN, Kariuki SM, Nyongesa MK, Mwangi P, Chongwo E, Newton CR, et al. Cognition, mood and quality-of-life outcomes among low literacy adults living with epilepsy in rural Kenya: a preliminary study. *Epilepsy Behav*. 2018;85:45–51.
- Englot DJ, Chang EF. Rates and predictors of seizure freedom in resective epilepsy surgery: an update. *Neurosurg Rev*. 2014;37:389–404. discussion 404–385, 405.
- Kissani N, Nafia S, El Khiat A, Bengamara N, Maiga Y, Sogoba Y, et al. Epilepsy surgery in Africa: state of the art and challenges. *Epilepsy Behav*. 2021;118:107910.
- Barsi P, Kenéz J, Solymosi D, Kulin A, Halász P, Rásonyi G, et al. Hippocampal malrotation with normal corpus callosum: a new entity? *Neuroradiology*. 2000;42:339–45.
- Janszky J, Woermann FG, Barsi P, Schulz R, Halász P, Ebner A. Right hippocampal sclerosis is more common than left after febrile seizures. *Neurology*. 2003;60:1209–10.
- Medana IM, Chaudhri G, Chan-Ling T, Hunt NH. Central nervous system in cerebral malaria: ‘Innocent bystander’ or active participant in the induction of immunopathology? *Immunol Cell Biol*. 2001;79:101–20.
- Fawcett JW, Asher RA. The glial scar and central nervous system repair. *Brain Res Bull*. 1999;49:377–91.

36. Sahu PK, Hoffmann A, Majhi M, Pattnaik R, Patterson C, Mahanta KC, et al. Brain magnetic resonance imaging reveals different courses of disease in pediatric and adult cerebral malaria. *Clin Infect Dis*. 2020;73:e2387–96.
37. Burton KJ, Rogathe J, Whittaker R, Mankad K, Hunter E, Burton MJ, et al. Epilepsy in Tanzanian children: association with perinatal events and other risk factors. *Epilepsia*. 2012;53:752–60.
38. Fisher JL, Schwartzbaum JA, Wrensch M, Wiemels JL. Epidemiology of brain tumors. *Neurol Clin*. 2007;25:867–90.
39. Kariuki SM, Chengo E, Ibinda F, Odhiambo R, Etyang A, Ngugi AK, et al. Burden, causes, and outcomes of people with epilepsy admitted to a rural hospital in Kenya. *Epilepsia*. 2015;56:577–84.
40. He HJ, Shen TZ, Chen XR, Feng XY, Jiang CC, Gao X. Prognostic value of MRI and 1H MRS in patients with temporal lobe epilepsy. *Zhonghua Yi Xue Za Zhi*. 2003;83:1586–91.
41. Engel J Jr. So what can we conclude—do seizures damage the brain? *Prog Brain Res*. 2002;135:509–12.
42. Mbuba CK, Ngugi AK, Fegan G, Ibinda F, Muchohi SN, Nyundo C, et al. Risk factors associated with the epilepsy treatment gap in Kilifi, Kenya: a cross-sectional study. *Lancet Neurol*. 2012;11:688–96.
43. Wagner RG, Kabudula CW, Forsgren L, Ibinda F, Lindholm L, Kahn K, et al. Epilepsy care cascade, treatment gap and its determinants in rural South Africa. *Seizure*. 2020;80:175–80.
44. Langat N, Kariuki S, Kamuyu G, Kakooza-Mwesige A, Owusu-Agyei S, Ae-Ngibise K, et al. Exposure to parasitic infections determines features and phenotypes of active convulsive epilepsy in Africa [version 1; peer review: awaiting peer review]. *Wellcome Open Res*. 2021;6:6.

SUPPORTING INFORMATION

Additional supporting information can be found online in the Supporting Information section at the end of this article.

How to cite this article: Kariuki SM, Wagner RG, Gunny R, D'Arco F, Kombe M, Ngugi AK, et al. Magnetic resonance imaging findings in Kenyans and South Africans with active convulsive epilepsy: An observational study. *Epilepsia*. 2024;65:165–176. <https://doi.org/10.1111/epi.17829>